zimmer | trauma

Radiograph Case Study #1

Zimmer® MotionLoc™ Screw with NCB Distal Femoral Plate

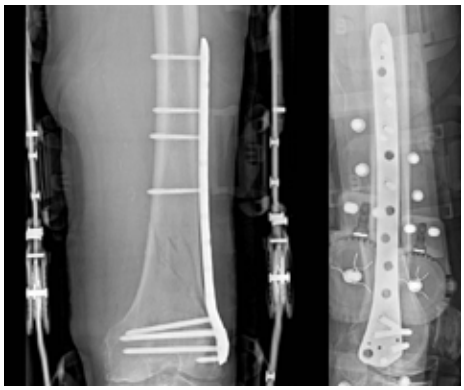

Patient Information: 85 year old male with pre-existing knee arthritis presenting with a supracondylar femur fracture as the result of a ground level fall.

Treatment: 10 Hole *Zimmer NCB* Distal Femoral Plate with 5 locking screws in the metaphysis and 4 *Zimmer MotionLoc* screws proximal to the fracture. No bone grafting or biologics were used to stimulate healing.

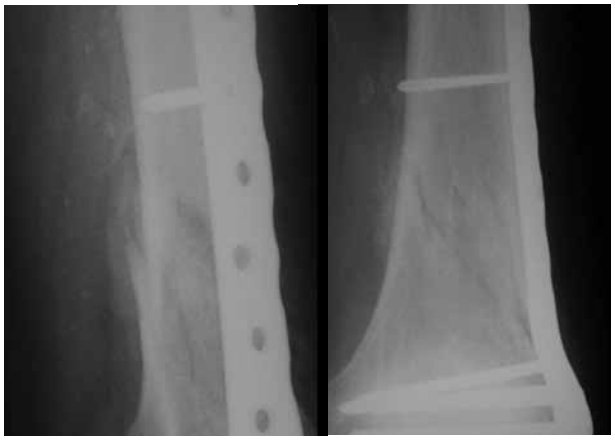

Follow up radiographs taken after 4 weeks of healing.

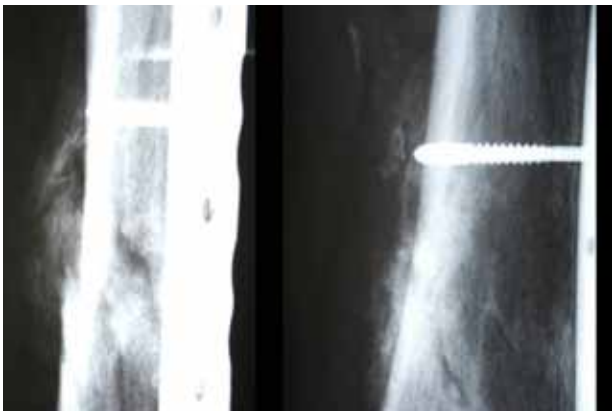

Follow up radiographs taken after 8 weeks of healing.

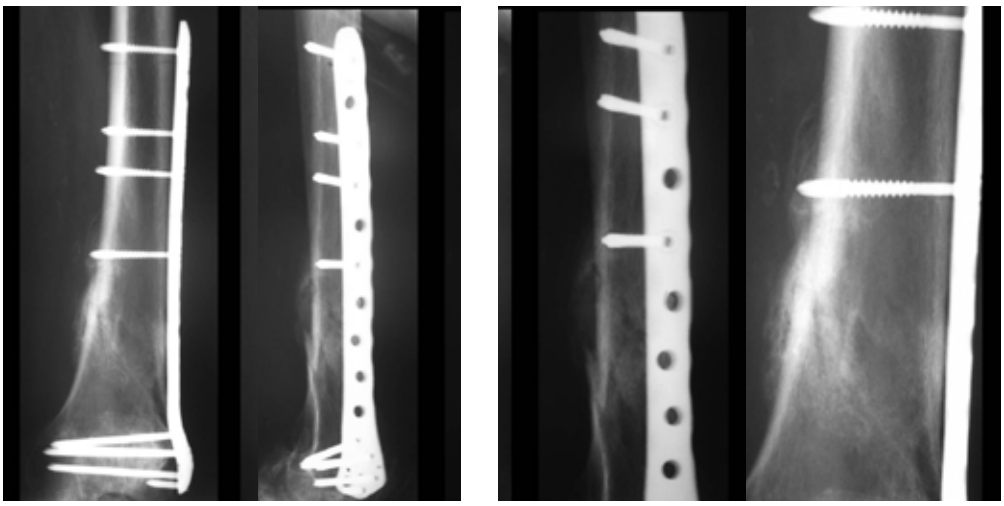

Follow up radiographs taken after 12 weeks of healing.

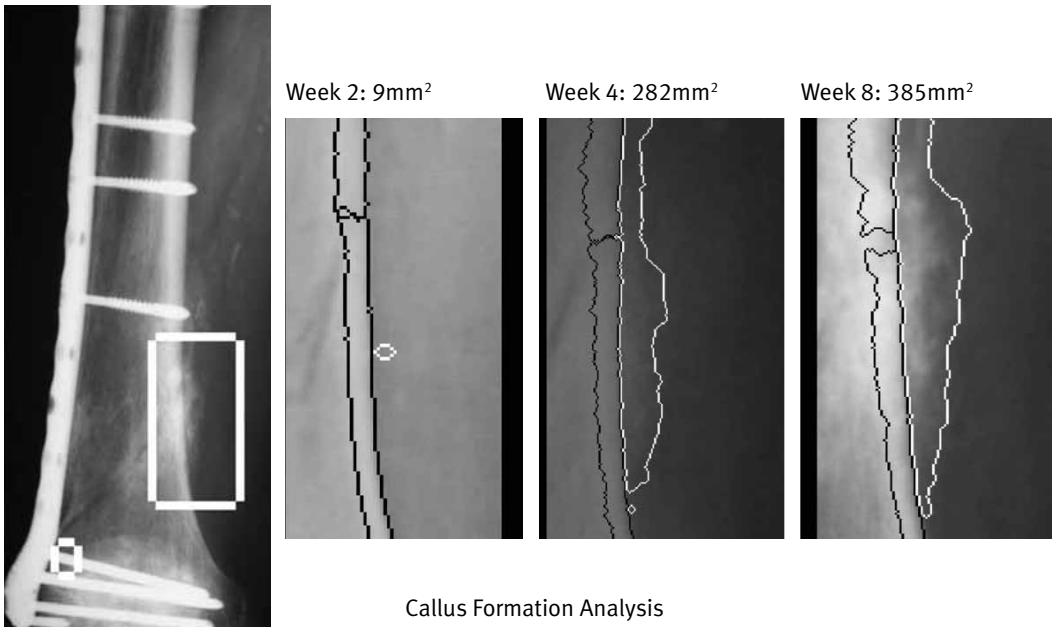

Callus Formation Analysis

An established computational algorithm was used to objectify the measurement of callus size.[1,2] Briefly, custom software extracts the size of periosteal callus from plain radiographs without the need for manual tracing of callus boundaries. The algorithm has been determined to measure callus area in surrogate models with an error less than 5%.[1,2]

1. Lujan TJ, Henderson CE, Madey SM, Fitzpatrick DC, Marsh JL, Bottlang M. Locked plating of distal femur fractures leads to inconsistent and asymmetrical callus formation. *J Orthop Trauma*.2010;24:156-162.
2. Lujan TJ, Madey SM, Fitzpatrick DC, Byrd GD, Sanderson JM, Bottlang M. A computational technique to measure fracture callus in radiographs. *J Biomech*. 2010;43:792-795.

Contact your Zimmer representative or visit us at www.zimmer.com

zimmer
Personal Fit. Renewed Life.™

©2011 Zimmer, Inc.